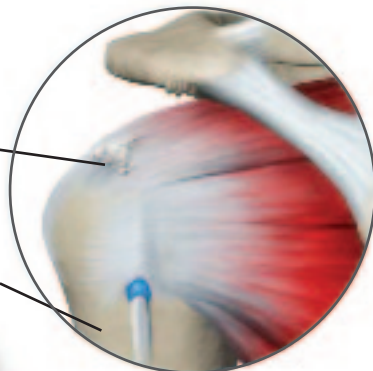


**MINI-OPEN ROTATOR CUFF REPAIR**

**SHOULDER JOINT  
BEFORE REPAIR**

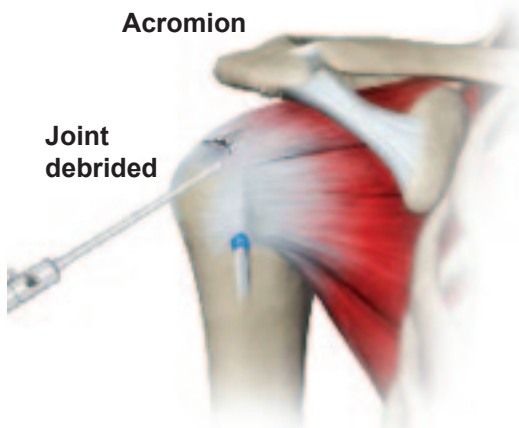Torn tendon

Humerus

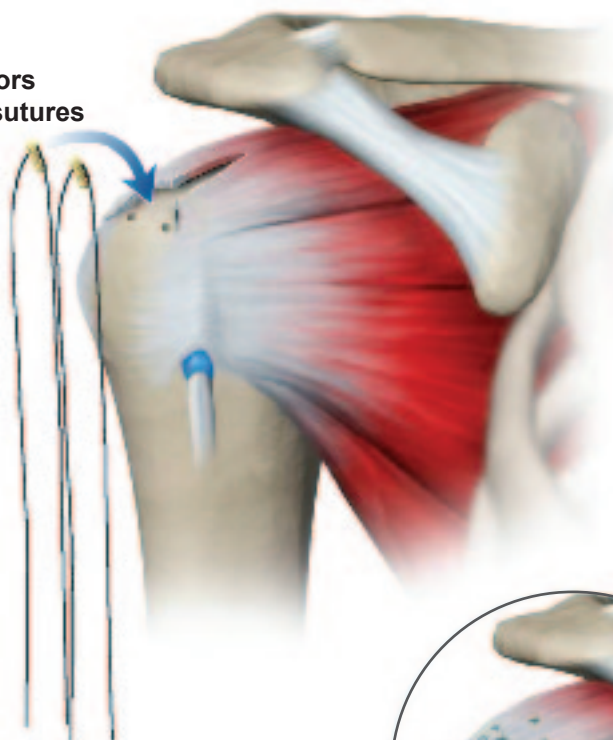


Acromion


Joint  
debrided



Anchors  
with sutures



**SHOULDER JOINT  
AFTER REPAIR**



**Overview**

This surgical procedure is used to inspect and reattach torn tendons in the shoulder's rotator cuff. The initial part of the surgery is performed arthroscopically through small tubes. An open incision may be needed if the damage is severe.

**Arthroscope Inserted**

The surgeon inserts a small video camera called an arthroscope through tiny incisions in the shoulder to inspect the damaged joint.

**Joint Debrided**

The surgeon removes any loose fragments of tendon or other debris from the damaged cuff tendon in the joint. This procedure, called debridement, is usually performed arthroscopically. Afterwards, the surgeon inspects the tissue damage in the joint and determines if more surgery is needed.

**Acromion Smoothed**

If bone spurs have formed on the bottom of the acromion, the surgeon uses a rasp-like tool to smooth the area. This is called subacromial decompression, or smoothing, and will keep the acromion from pinching down on the supraspinatus tendon. It is usually done arthroscopically.

**Rotator Cuff Examined**

If no tear is found in the rotator cuff area, the procedure may end here. If the surgeon finds a torn rotator cuff tendon, the type of repair needed is based on the size and severity of the tear. Smaller tears may be repaired arthroscopically, while larger ones (shown) may require an open incision of 2 to 3 inches. First, the torn end of the tendon is cleaned up. Next, an area on the humerus is cleared.

**Anchors Inserted**

The surgeon uses a drill or sharp tool to create one or more small holes in the bone. Anchors are then placed into the holes. The anchors hold stitches in place on the arm bone.

**Tear Sutured**

The tear in the tendon is stitched together. The sutures are pulled tightly against the anchors, reattaching the tendon to the humerus.

**End of Procedure**

After the surgery, the arm is usually placed in a sling. Physical therapy will be needed to regain full range of motion and increase shoulder strength. Over time, the tendon will firmly reattach to the humerus bone.