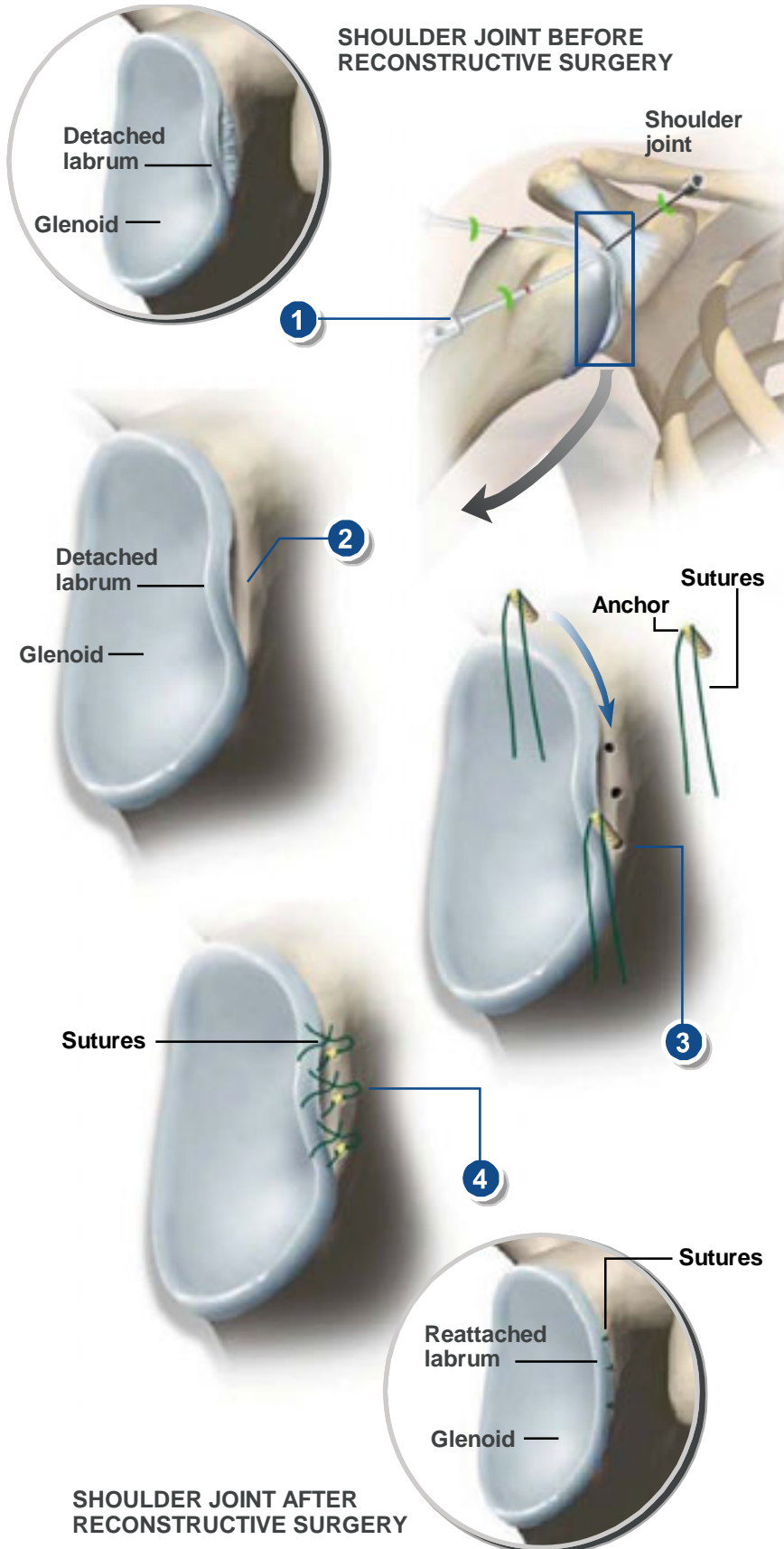


**ARTHROSCOPIC BANKART REPAIR**



**Overview**

This arthroscopic procedure is used to repair a detached labrum. The labrum is a thick band of cartilage attached to the glenoid. It lines the shoulder socket and helps keep the ball of the humerus in place.

**Arthroscope Inserted**

Small incisions are made in the front and back of the shoulder. The surgeon inserts a small video camera (called an arthroscope) to view inside the joint. Small instruments are inserted to perform the procedure.

**Area Cleaned**

The surgeon cleans the area around the detached labrum, removing any loose particles or rough edges.

**Anchors Placed**

The surgeon drills a few small holes in the bone near the detached labrum. Anchors are placed in the holes. These anchors are used to hold sutures in place around the glenoid.

**Labrum Reattached**

The surgeon attaches the sutures to the labrum and pulls the sutures tightly against the anchors, reattaching the labrum to the glenoid.

**End of Procedure**

The incisions can be closed with small bandages. After surgery, the arm is usually placed in a sling. Physical therapy will be needed to regain full range of motion and increased shoulder strength. Over time, the labrum will naturally reattach itself to the glenoid socket.